

Laser therapy in dogs and humans—is there a difference?

H.W. GOTTFRIED, E. BRANDLE, R. HEFTY, T. MATTFELDT*, W. BADURA†, U. VOGEL‡ and R.E. HAUTMANN

Urological Clinic and *Institute of Pathology, University of Ulm, †Institute of Veterinary Medicine, University of Wroclaw and ‡Institute of Pathology, Eberhard Karls University, Tübingen, Germany

Objective To compare quantitatively the reduction of volume of benign prostatic hyperplasia (BPH) achieved by laser therapy in dogs and men.

Patients, materials and methods Twelve mongrels, with a mean prostatic volume of 33.4 mL, underwent transurethral laser treatment using an Nd:YAG laser with an Ultraline® fibre at 60 W power setting. The reduction in prostatic volume was assessed quantitatively 3 months after treatment using stereological methods. Forty patients (mean age 70.2 years, range 51–84) with symptomatic BPH (pre-operative mean prostate volume 46.3 mL) were treated under similar operative conditions with the same laser, power and fibre system. Their urinary performance was assessed before and 6 months after treatment using urinary flow rates, residual volume and a symptom score, and

their prostatic volume and necrosis assessed using transrectal ultrasonography.

Results After laser treatment, the mean reduction in the dog prostate volume was 50% and in the patients was only 21%. The different impact was probably caused by anatomical differences between the human and dog prostate; the human prostate consists mainly of stromal tissue and the canine prostate of glandular epithelium.

Conclusions The canine model gives only an approximate guide to the extent of tissue destruction that laser treatment can achieve in men with BPH. Furthermore, tissue differences between men may also affect the response to laser treatment.

Keywords Benign prostatic hyperplasia, volume reduction, laser therapy, dog, human

Introduction

BPH is a disease of outstanding medical and socio-economic significance; in the USA, more than one-third of all men up to the age of 80 years undergo surgical treatment for BPH [1]. The gold standard treatment is TURP which, although it has a low mortality of 0.2–0.4% [2,3], has a considerable morbidity of about 20% [2–5]. One serious complication of TURP is haemorrhage requiring blood transfusion [2] and other characteristic complications are urethral stricture and bladder neck sclerosis, occurring in about 5% of patients [6]. For these reasons, other methods of treatment have been under scrutiny for several years.

BPH in the dog is generally accepted as a model for testing the effectiveness of both instrumental and drug treatment. This study, the first of its kind, compares the effectiveness of laser therapy for BPH in dog and man, assessing the reduction in prostate volume as the measure of outcome.

Patients, materials and methods

The dog model

Twelve mature male mongrel dogs (age 4–12 years) underwent laser treatment of the prostate under intubation anaesthesia. To improve the endoscopic access to the prostatic urethra, the first operative step in each dog was to make a buttonhole incision. All the prostates were imaged by TRUS, using a 7.5 MHz ultrasound head (Kretz) with a Kretz Kombison 310 ultrasound unit. Under TRUS guidance, trocars were then inserted via the perineum into the marginal zones of the prostate and probes for continuous temperature measurement inserted via the trocars.

Transurethral laser treatment was then carried out using an Nd:YAG laser operating at 1.064 nm in conjunction with an Ultraline®-fibre (Haereus, Germany). Energy was applied continuously at 60 W in continuous-wave mode. The fibre produces an energy density of 5.1 W/cm² at a target distance of 2 mm and 60 W output [7]. In the fibre head, the fibre beam is deflected through a prism at an angle of 80° with a divergence of 18°; the fibre tip (6 F) with the prism is protected by quartz, thus permitting direct contact with the tissue.

Accepted for publication 29 October 1996

The prostatic urethra was irradiated continuously with the laser beam, beginning at the bladder neck and extending to the colliculus seminalis, by gradually withdrawing the fibre. Standard cystoscopes (19.5 F) were used, with normal saline (0.9%) for intra-operative irrigation. Throughout the application of energy and for up to 5 min after completing the treatment, the temperature in the outer zones of the prostate, including the pararectal area, was measured by the temperature sensors.

Of the 12 dogs, four were killed within the first week from treatment, a further four at 4 weeks and the remaining four at 12 weeks. In those dogs killed at 12 weeks, TRUS was performed immediately after death to detect any laser-induced intra-prostatic cavities and the prostates from all the dogs were examined histologically. The extent of the necrotic zones in the prostate was quantified using stereological methods. After the prostates were fixed whole in formalin, they were cut into slices 5 mm thick with a precision slicing machine (Fig. 1). After embedding in paraffin wax, large sections were cut from each slice. The outlines of the prostate slices were drawn under direct vision using a light microscope and the zones of necrosis outlined with a fine pen. Each of the large sections thus marked was projected on to a point grid, and the total number of points counted in the necrotic zones, divided by the total number of points in the prostate, provided an undistorted estimate of the proportion by volume of necrotic tissue in the prostate.

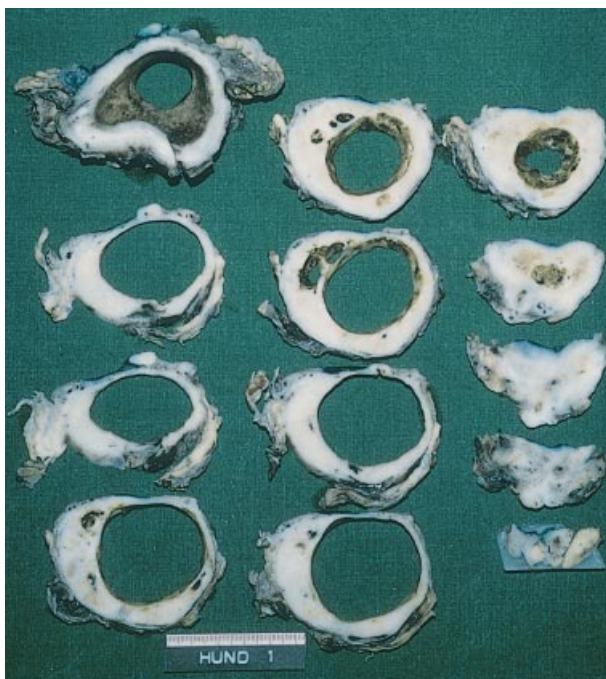

Fig. 1. A dog prostate after laser therapy. Slices cut at 5 mm show definite areas of necrosis.

Patients

As part of a prospective multicentre study, 40 patients (mean age 70.2 years, range 51–84) were investigated in our hospital. In all patients, the indication for laser therapy was symptomatic BPH with a significant residual urine volume. All patients underwent a thorough physical examination, including a DRE, before laser therapy. A sextant biopsy of the prostate was taken pre-operatively in all patients to exclude those with prostatic carcinoma. The size of the prostate was measured pre-operatively using TRUS with a biplanar 7.5 MHz head and a Kombison 530 ultrasound instrument (Kretz). The volume of the prostate was calculated from the formula: transverse dimension \times anterior/posterior dimension \times craniocaudal dimension \times 0.52 [8]. To assess changes in urinary performance, the maximum urinary flow rate (Q_{max}) and post-void residual urine volume (PVR) were determined pre-operatively and the patients' symptoms were assessed using the AUA-7 symptom score.

Operative technique

Laser therapy was applied as transurethral laser ablation of the prostate (TULAP), using continuous irrigation with 0.9% saline and a special 24 F laser resectoscope (Wolff, Germany) with a straight working channel. The laser beam was applied at 60 W output in continuous-wave mode. In all patients, the prostatic urethra was irradiated continuously, starting at the bladder neck at the 2, 4, 8 and 10 o'clock positions and withdrawing the fibre slowly down to the apex of the prostate (Fig. 2).

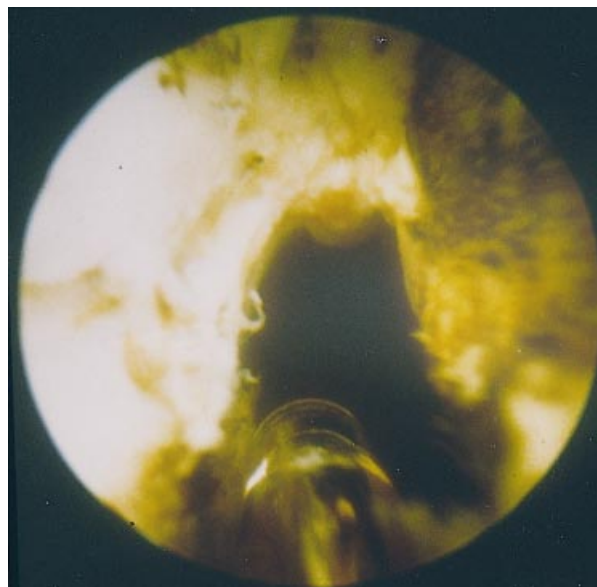


Fig. 2. Prostatic urethra (patient) at the end of laser treatment (endoscopic view).

At the end of the operation, a 20 F catheter was left in place for 48 h.

All 40 patients were assessed 6 months after laser therapy and the Q_{max} , PVR and AUA-7 symptom score re-assessed. The total volume of the prostate was measured by TRUS and any cavities induced by laser therapy noted.

Student's *t*-test was used to assess differences between pairs of means, with significance indicated at $P < 0.05$.

Results

The dog model

The mean (SD) pre-operative prostatic volume in the dogs was 33.4 (± 24.5) mL and the mean (SD) laser energy applied was 37.5 kJ (± 17.8). The highest temperature measured in the outer zones of the prostate or between the prostate and rectum was 42.2°C. As determined stereologically, the mean (SD) proportion (by volume) occupied by areas of necrosis 3 months after treatment was 50 (± 23)% (Figs. 1 and 3a).

Patients

The changes in the variables assessed in the men with BPH are shown in Table 1. In 19 patients (48%), TRUS showed a detectable intraprostatic cavity 6 months after laser therapy (Fig. 3b). The mean (SD) laser energy applied to the patients was 111.1 kJ (± 54.4).

In none of the 40 patients was laser treatment followed by any serious complications such as the TUR syndrome or haemorrhage requiring blood transfusion. A urinary tract infection needing treatment occurred in 14 of the 40 patients (30%), epididymitis occurred in three (7.5%) within the first 8 weeks after laser therapy and erectile dysfunction, occurring for the first time post-operatively, was reported in one (2.5%). Four of the 40 patients (10%) subsequently underwent conventional TURP because of persistent obstruction.

Discussion

BPH in dogs is generally accepted as a model for testing methods of treating BPH in men. Previous experiments in dogs have shown that laser treatment can achieve dramatic reductions in the volume of BPH [9,10]. In the present animal experiments there was an equally impressive and substantial destruction of BPH tissue using the laser. The extent of laser-induced tissue necrosis has not been investigated quantitatively before; estimated stereologically, the prostatic tissue in the dog was shown to be reduced by half and the effect was also visible on TRUS as large intraprostatic necrotic areas.

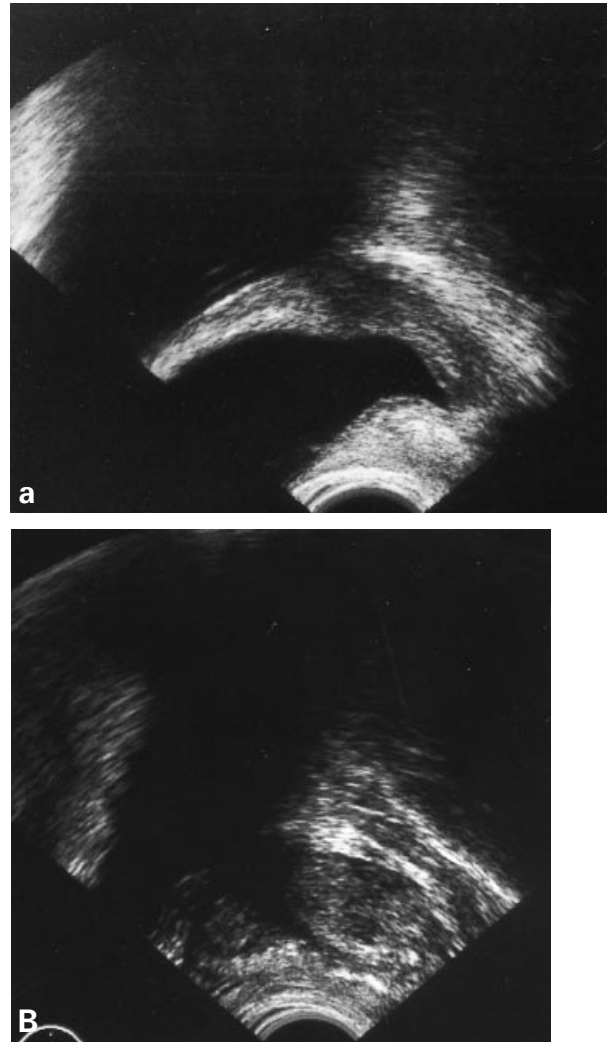


Fig. 3. TRUS (longitudinal view) showing intraprostatic cavities after laser therapy in (a) a dog and (b) a patient.

When these results are compared with those obtained in man, there is a clear difference; although about half the present patients had a laser-induced necrotic zone detectable by TRUS 6 months after laser therapy, the necrosis was much less pronounced than it was in the dog (Fig. 3). The reduction in prostatic volume in the patients was only 21%, much less than that achievable in dogs.

This is surprising, given that the conditions of treatment were similar in both, using the same fibre system, laser and wavelength and with comparable operative techniques. The only difference was the mean laser energy applied, which was 35.5 kJ in dogs, considerably lower than the 111 kJ applied to the men. However, other studies [11,12] using the same laser system show that better functional indices can be attained in men by increasing the applied energy.

We propose that the differences between dog and man

	Before (mean [SD])	6 months after (mean [SD])	P
Prostatic volume (mL)	46.3 (±14.3)	36.3 (±12.7)	<0.0015
(% change)		21 (±13.6)	
AUA-7	26.8 (±2.5)	7.5 (±5.1)	<0.001
PVR (mL)	185.5 (±71.6)	52.1 (±72.3)	<0.001
Qmax (mL/s)	7.6 (±2.8)	18.4 (±9.4)	<0.001

Table 1 The changes in the variables assessed before and after TULAP

in the reduction of prostatic volume induced by laser treatment arise from structural differences in the prostate. According to Bartsch *et al.* [13], human BPH predominantly affects stromal tissue but in dogs, glandular epithelial hyperplasia predominates [14]. We believe that this species-related structural difference in the prostate is responsible for the disparate responses of the two species to laser energy. These results seem to reflect a constant phenomenon, given that other research groups have achieved definite zones of necrosis in experimental animals [9,10], although zones of similar dimensions were not attainable in patients [15]. As heat is the major factor acting on the tissues during laser treatment, we consider it likely that the results obtained with the laser will be applicable to other thermal methods of treatment.

Thus, we conclude that experiments in dogs allow only an approximate estimate of the extent of tissue destruction attainable during treatment for BPH in man and that differences between men in the distribution of the stromal and glandular epithelial components of BPH may constitute an important prognostic factor governing the individual response of human BPH to laser therapy.

References

- 1 Barry MJ. Epidemiology and natural history of benign prostatic hyperplasia. *Urol Clin North Am* 1994; **17**: 495–507
- 2 Mebust WK, Holtgrewe HL, Cockett ATK, Peters PC, Writing Committee. Transurethral prostatectomy: immediate and postoperative complications. A cooperative study of 13 participating institutions evaluating 3885 patients. *J Urol* 1989; **141**: 243–7
- 3 Melchior H, Seabert J. Wie risikoreich ist die transurethrale Resektion der Prostata (TURP)? *Urologe [B]* 1993; **33**: 375–7
- 4 Holtgrewe HL, Valk WL. Factors influencing the mortality and morbidity of transurethral prostatectomy. A study of 2015 cases. *J Urol* 1962; **87**: 450–9
- 5 Melchior H, Valk WL, Foret JD, Mebust WK. Transurethral prostatectomy: computerized analysis of 2223 consecutive cases. *J Urol* 1974; **112**: 634–42
- 6 Mebust WK, Holtgrewe HL. Current status of transurethral

- 7 van Swol CFP, Verdaasdonk RM, Moonibroek J, Lock TMTW, Boon TA. Prediction of the necrotic zone depending on the optical and thermal characteristics of laser prostatectomy modalities. *J Urol* 1994; **151**: 332 A (Abstract 419)
- 8 Terris MK, Stamey TA. Determination of prostate volume by transrectal ultrasound. *J Urol* 1991; **145**: 984–7
- 9 Johnson DE, Price RE, Croomens DM. Pathologic changes occurring in the prostate following transurethral laser prostatectomy. *Laser Med Surg* 1992; **12**: 254–63
- 10 Roth RA, Aretz TH. Transurethral ultrasound-guided laser-induced prostatectomy (TULIP procedure): a canine feasibility study. *J Urol* 1991; **146**: 1128–35
- 11 Fournier G, Narayan P. Factors affecting size and configuration of Neodymium: YAG (Nd:Yag) laser lesions in the prostate. *Laser Med Surg* 1994; **14**: 314–22
- 12 Narayan P, Fournier G, Induhara R, Leidich R, Kandingermann A. Transurethral evaporation of prostate (TUEP) with Nd:YAG laser using a contact free beam technique: results in 61 patients with benign prostatic hyperplasia. *Urology* 1994; **43**: 813–20
- 13 Bartsch G, Muller G, Oberholzer M, Rohr HP. Light microscopic stereological analysis of the normal human prostate and of benign prostatic hyperplasia. *J Urol* 1979; **122**: 487–91
- 14 Metzger B. Histologische, ultrastrukturelle und histochemische Untersuchungen an der Prostata des Hundes. Inaugural-Dissertation (Munchen) 1993
- 15 Schulze H, Martin W, Hoch P, Pannek J, Haupt G, Senge TH. Transurethral ultrasound guided laser-induced prostatectomy: clinical outcome and data analysis. *Urology* 1995; **45**: 241–7

Authors

H.W. Gottfried, Senior Urologist.

E. Brandle, Resident.

R. Hefty, Resident.

T. Mattfeldt, Professor of Pathology.

W. Badura, Professor of Veterinary Medicine and Head of Department.

U. Vogel.

R.E. Hautmann, Professor of Urology and Head of Department.

Correspondence: Dr H.W. Gottfried, Urologische Universitätsklinik, Prittwitzstrasse 43, W-89075 Ulm, Germany.